

The impact of cognitive reserve in the recovery of chronic encephalopathy associated with traumatic brain injury – part one

Silvina Ilut^{1,2}, Irina Maria Vlad^{1,2}, Dafin Muresanu^{1,2}

Author Affiliations

1. Department of Neuroscience, Iuliu Hatieganu University of Medicine and Pharmacy, Cluj-Napoca, Romania

2. RoNeuro Institute for Neurological Research and Diagnostic, Cluj-Napoca, Romania

DOI

10.25122/jml-2022-1004

Dates

Received: 12 March 2022

Accepted: 5 April 2022

CHRONIC TRAUMATIC ENCEPHALOPATHY (CTE)

Definition

Chronic traumatic encephalopathy (CTE) represents a neurodegenerative disease that appears after repetitive head impacts. It is characterized by hyperphosphorylated tau (p-tau) deposits in the sulcus. Currently, CTE can be diagnosed based only on neuropathological examination.

The main categories of symptoms for CTE manifest as:

- Cognitive impairment at the mean age of 60, and then progressing to dementia;
- Behavioral changes at approximately the age of 35 and then progressing to cognitive impairment.

Etiology

Recurrent closed traumatic brain injury (especially mild TBI) is the incriminated causative factor of CTE. Although, sometimes, the causative TBI can also be singular [1, 2].

Furthermore, CTE can be associated with post-traumatic encephalopathy or a single disease.

Generally, the most incriminated activities associated with CTE are contact sports, but not exclusively (Figure 1) [3–6]. Other situations that correlate with CTE are the explosions encountered among military personnel and domestic abuse.

Risk Factors

- Genetic risk factors (ApoE3 or ApoE4 allele);
- Age at the time of TBI (or repetitive TBI): younger or older age;
- Military service;
- Epilepsy;
- Length of sports participation;
- Head trauma [3].

Pathophysiology & Epidemiology

From an epidemiological perspective, most cases of CTE among athletes, with a percentage of 30% [6], have microscopic lesions that comprise mechanical damage to neurons, glia cells, and brain blood vessels secondary to the applied forces (acceleration, deceleration, rotation).

Generally, from a pathophysiology point of view, the microscopic lesions leading to CTE comprise mechanical damage to neurons, glia cells, and brain blood vessels that are secondary to the applied forces (acceleration, deceleration, rotation).

The distinct types of lesions, similarly to Alzheimer's disease, range from:

- Micro-bleeds;
- Axonal injury;
- Loss of blood-brain barrier;
- Inflammation;
- The accumulation of hyperphosphorylated tau (p-tau) protein;
- Neurofibrillary tangles.

Followingly, it is also called tauopathy.

Furthermore, the amount of traumatic brain injury that leads to CTE and other potential factors that might be causative agents is currently unknown [2–4].

Clinical Presentation

The clinical manifestation of CTE varies from the most common cognitive and behavioral changes to disorders of sensation and motility.

The onset can overlap with signs and symptoms of the acute phase of traumatic brain injury, but it can also develop with a delay of up to tens of years after the episode of trauma. Usually, the onset is after about 8–10 years [7] and its age varies between the 20s and 70s, though most athletes already have the first signs and symptoms by the time they retire from sports practice [8].

Clinical signs and symptoms of CTE may include (Figure 2) [2, 5, 8, 9]:

- Mood;
- Cognition;
- Motor;
- Behavior.

Diagnosis

Unfortunately, the diagnosis can currently be made only neuropathologically during the postmortem examination [3, 4, 10]. This is also one of the disadvantages regarding knowledge about this disease since the information is usually from retrospective cases and the statements of different family members of the

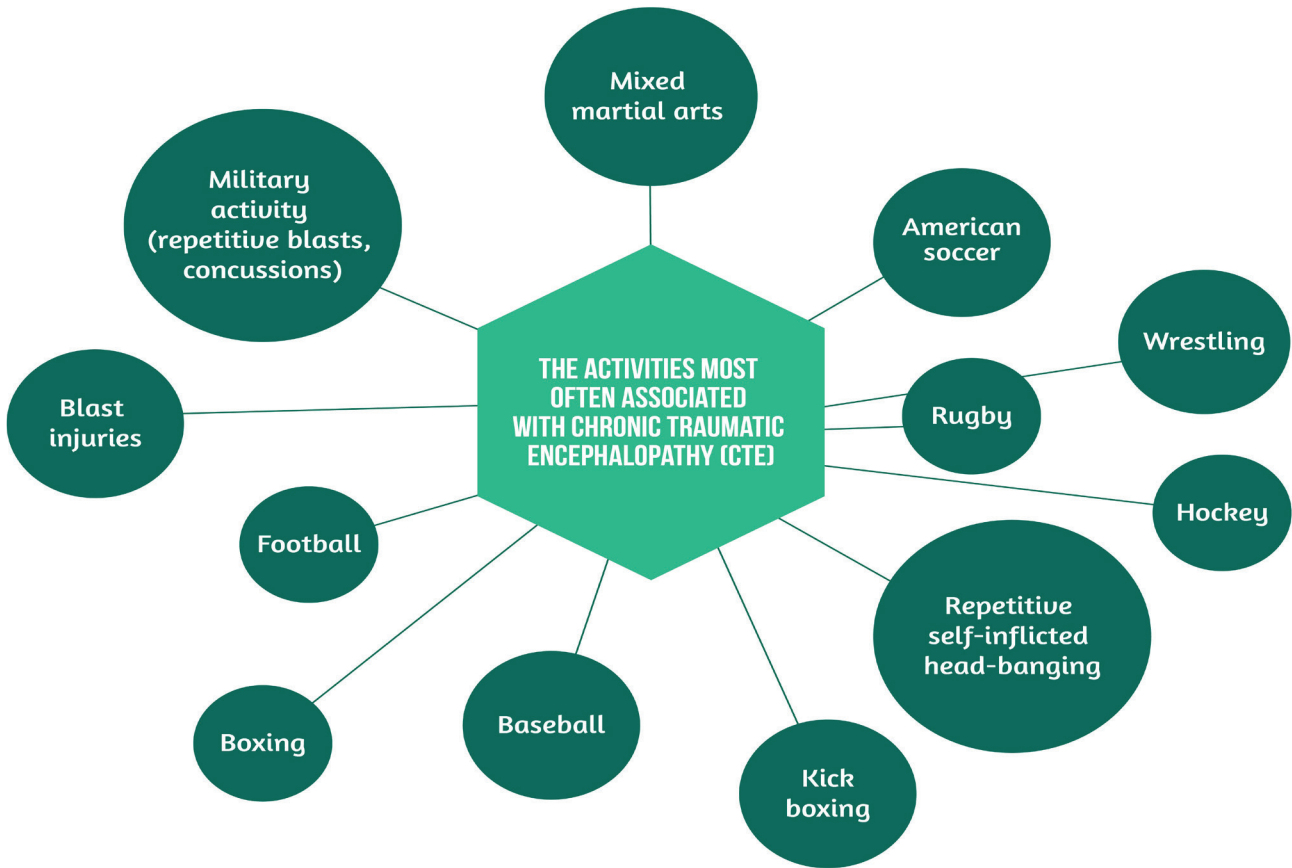


Figure 1. The activities most often associated with CTE.

affected patients. The imagery used in clinical practice does not bring information about the disease as it can seem to be normal.

Prevention

The importance of CTE prevention stems from its critical consequences and its impact on the affected individuals and their families. In addition, the omission of this diagnosis during life in several patients also occurs.

The continuous progression of the disease is associated with significant changes in the quality of life ranging from:

- Social dysfunction;
- Financial problems;
- Paranoia;
- Suicidal ideations;
- Different phobias;
- Interpersonal relationship dysfunction (divorce, domestic abuse);

CLINICAL SIGNS AND SYMPTOMS OF CTE:

MOOD	paranoia, depression, hopelessness, irritability
COGNITION	memory problems, disorientation, confusion, executive dysfunction, dementia
MOTOR	parkinsonism, bradykinesia, tremor, ataxia, dysarthria, dizziness, speech problems, wide gate, ocular abnormalities
BEHAVIOUR	impulsivity, irritability, depression, suicidality, violent outbursts, explosivity, and aggression

Figure 2. Clinical signs and symptoms of CTE.

- Trouble with sleep;
- Substance misuse and abuse [8].

Several prevention strategies have been adopted, from the use of helmets and mouthguards to the establishment of different protocols for athletes that clear state rules that have to be followed before their reintroduction into play and to changes of rules in sports [11]. It is vital to have a multidisciplinary involvement, for example, in sports: from referees to coaches to policymakers and physicians. Additionally, because the military personnel are at risk during combat, physical exercises, other sports, or recreational activities, several protective gears and protocols are in place to ensure their protection as much as possible [12].

The second part will discuss the cognitive reserve and rehabilitation associated with CTE.

REFERENCES

1. Omalu B. Chronic traumatic encephalopathy. *Prog Neurol Surg.* 2014;28: 38-49. doi: 10.1159/000358761.
2. Inserra CJ, DeVrieze BW. Chronic Traumatic Encephalopathy. In: StatPearls. Treasure Island (FL): StatPearls Publishing; 2022. Available from: <https://www.ncbi.nlm.nih.gov/books/NBK470535/>
3. McKee AC, Stein TD, Kiernan PT, Alvarez VE. The neuropathology of chronic traumatic encephalopathy. *Brain Pathol.* 2015 May;25(3):350-64. doi: 10.1111/bpa.12248.
4. Takahata K, Tabuchi H, Mimura M. Late-onset Neurodegenerative Diseases Following Traumatic Brain Injury: Chronic Traumatic Encephalopathy (CTE) and Alzheimer's Disease Secondary to TBI (AD-TBI). *Brain Nerve.* 2016 Jul;68(7):849-57. Japanese. doi: 10.11477/mf.1416200517.
5. Baugh CM, Robbins CA, Stern RA, McKee AC. Current understanding of chronic traumatic encephalopathy. *Curr Treat Options Neurol.* 2014;16(9):306. doi: 10.1007/s11940-014-0306-5.
6. Maroon JC, Winkelman R, Bost J, Amos A, *et al.* Chronic Traumatic Encephalopathy in Contact Sports: A Systematic Review of All Reported Pathological Cases. *PLOS One.* 2015;10(2): e0117338. doi: 10.1371/journal.pone.0117338.
7. McKee AC, Cantu RC, Nowinski CJ, Hedley-Whyte ET, *et al.* Chronic traumatic encephalopathy in athletes: progressive tauopathy after repetitive head injury. *J Neuropathol Exp Neurol.* 2009;68(7):709-35. doi: 10.1097/NEN.0b013e3181a9d503.
8. Saulle M, Greenwald BD. Chronic traumatic encephalopathy: a review. *Rehabil Res Pract.* 2012;2012:816069. doi: 10.1155/2012/816069.
9. Fesharaki-Zadeh A. Chronic Traumatic Encephalopathy: A Brief Overview. *Front Neurol.* 2019 Jul 3;10:713. doi: 10.3389/fneur.2019.00713.
10. Asken BM, Sullan MJ, DeKosky ST, Jaffec MS, Bauer RM. Research Gaps and Controversies in Chronic Traumatic Encephalopathy: A Review. *JAMA Neurol.* 2017 Oct 1;74(10):1255-1262. doi: 10.1001/jamaneurol.2017.239.
11. Concannon LG, Kaufman MS, Herring SA. Counseling athletes on the risk of chronic traumatic encephalopathy. *Sports Health.* 2014;6(5):396-401. doi: 10.1177/1941738114530958.
12. Stein TD, Alvarez VE, McKee AC. Chronic traumatic encephalopathy: a spectrum of neuropathological changes following repetitive brain trauma in athletes and military personnel. *Alzheimers Res Ther.* 2014;6(1):4. doi: 10.1186/alzrt234.